

## Introduction:

Clinical and imaging tumor size measurement is the current standard of care for evaluating breast cancer response to neoadjuvant chemotherapy (NACT). However, tumor size changes often lag behind functional changes during treatment [1] and fail to provide early prediction of therapy response, which is an important prerequisite for rapid adoption of alternative treatment regimen for non-responding patients and achieving the goal of personalized care. In addition, breast tumor size measured by imaging after NACT may over- or under-estimate residual disease [2], causing inappropriate surgical decision making of breast conservation vs. mastectomy. By measuring the magnitude of tumor microvascular property changes, dynamic contrast-enhanced (DCE) MRI has been shown capable of providing early prediction of breast cancer response to NACT [1,3]. Since heterogeneity is an important feature of malignant tumors, the utility of image texture analysis has been increasingly investigated for cancer diagnosis and therapeutic monitoring. A recent study [4] indicates that pre-NACT breast tumor MRI texture features, extracted directly from raw  $T_1$ -weighted DCE images, may be useful for prediction of therapy response. In this preliminary study, we sought to evaluate the utility of 3D texture analysis [5,6] of DCE-MRI based pharmacokinetic (PK) parametric maps for early prediction of breast cancer therapy response.

## Methods:

Twenty-eight women with locally advanced breast cancer who underwent NACT consented to research DCE-MRI studies performed at visit 1 (V1, before NACT), V2 (after first NACT cycle), V3 (midpoint of NACT, usually after three NACT cycles), and V4 (after NACT completion before surgery). 3D DCE-MRI data acquisition details are described in [3]. Tumor ROIs were drawn on post-contrast DCE image slices covering the spatial extent of the tumor by experienced radiologists. Pixel-by-pixel (within the ROI) DCE time-course data were subjected to both the Standard Tofts Model (SM) [7] and Shutter-Speed Model (SSM) [8] PK analyses to extract  $K^{trans}$ ,  $v_e$ ,  $k_{ep}=K^{trans}/v_e$ , and  $\tau_i$  (mean intracellular water lifetime, SSM-only parameter) parameters. The SSM accounts for the effects of transcytolemmal water exchange kinetics. The  $dK^{trans}=[K^{trans}(SSM)-K^{trans}(SM)]$  parameter, a measure of water exchange effects on  $K^{trans}$  estimation, was also calculated. Pathologic response to NACT and residual cancer burden (RCB) for each tumor were determined by pathology analyses of post-NACT resection specimens using previously published methods [9,10], with RCB = 0 indicating pathologic complete response (pCR).

The PK analysis generated 3D tumor ROI parametric maps, from which we extracted three statistical matrices to characterize textures of these maps [5,6]: the Co-Occurrences Matrix (COM, a tabulation of how often different combinations of pixel brightness values occur in an image in a given offset), the Run Length Matrix (RLM, counting the run length with the same gray level in a given direction) and the Size Zone Matrix (SZM, counting the number of connected zones of a given size and of a given intensity). Both COM and RLM have a directional parameter. Therefore many matrices were computed (one for each direction) and then merged. Fifteen texture features were extracted from these matrices (Haralick features from COM, moments from RLM and SZM [5, 6]).

Only the ability of PK parameter texture analysis for early prediction of therapy response was investigated in this study. Thus we used only the V1 and V2 features, as well as the subtraction of V2 feature values from V1 to capture the changes after one NACT cycle. For every PK parametric map, the predictive ability for RCB score was assessed using linear regression for every features triplet (due to the small sample size, we used only three features at a time out of the 15) from each of the three texture matrices. The validation was performed with the leave-one-out protocol. Three correlations were used to confirm the results: Pearson's product moment (linear), Spearman's rank-order (rank) and Kendall's Tau (rank) correlation coefficients. We also investigated which parametric maps were more often used in texture features that gave good correlations. The frequency of the parametric map having all three correlation values greater than 0.7 under all possible combinations of triple features was computed.

## Results:

According to pathology analyses of surgery specimens, 5 patients were pCRs (RCB = 0), while the other 23 patients were non-pCRs with a RCB range of 0.433 – 3.707. Table 1 lists for each of the three texture analysis methods the PK parameter map with the highest correlation coefficients, which were obtained from changes in texture features after one NACT cycle (V2 relative to V1). High correlation coefficient values indicate high capabilities for early prediction of response to NACT. Figure 1 shows how often several PK parameter maps were used in texture analysis to produce good correlations with RCB scores with all three correlation coefficients > 0.7. It appears that the SSM maps of  $k_{ep}$ ,  $\tau_i$  and  $K^{trans}$ , rather than the SM maps of  $k_{ep}$ ,  $v_e$  and  $K^{trans}$ , were most often selected in triple-feature texture analysis to provide good early prediction of therapy response.

## Discussion and Conclusion:

This preliminary study demonstrates that changes in 3D texture features of DCE-MRI based PK parametric maps in the early phase of NACT can be effective for prediction of eventual breast cancer RCB score, and thus pathologic response to NACT. The use of the powerful 3D statistical matrices produced high RCB score correlations and allowed automatic determination of the PK parametric maps whose feature changes are most likely to be useful for predicting tumor therapy response. The SSM PK parameter values estimated from the same DCE-MRI data are generally larger than the SM counterparts [11], generating greater parameter dynamic ranges in SSM parametric maps. This may be the reason why SSM maps are more often utilized than SM maps in texture analysis for good prediction of therapy response. The findings from this limited cohort size need to be validated with a larger cohort. Furthermore, for the purpose of assessing therapy response it would be valuable to compare texture analyses of PK parametric maps and raw MRI images and determine which approach is more effective, or if there is added value in combining the two approaches.

**Grants Support:** NIH U01 CA154602, Keck foundation and NSF award 1027834.

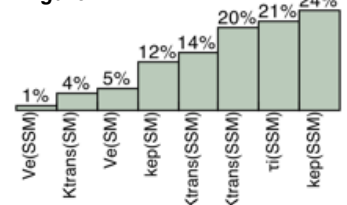
## References:

[1] Marinovich *et al.*, *The Breast* 2012;21:669-77. [2] Partridge *et al.*, *AJR* 2002;179:1193-9. [3] Tudorica *et al.*, *PISMRM* 2014;22:920. [4] Teruel *et al.*, *NMR Biomed* 2014;27:887-96. [5] Thibault *et al.*, *IJPRAI* 2013;27:no.1. [6] Thibault *et al.*, *IEEE Trans BME* 2014;61:630-7. [7] Tofts *et al.*, *JMRI* 1999;10:223-32. [8] Yankeelov *et al.*, *Magn Reson Med* 2003;50:1151-69. [9] Symmans *et al.*, *J Clin Oncol* 2007;25:4414-22. [10] Rajan *et al.*, *Cancer* 2004;100:1365-73. [11] Huang *et al.*, *Radiology* 2011;261:394-403.

**Table 1: Correlation Coefficients between PK Parametric Map Feature Changes and RCB Score**

Method	PK Map	Spearman	Pearson	Kendall
COM	$k_{ep}(SM)$	.97	.88	.90
SZM	$K^{trans}(SSM)$	.92	.90	.80
RLM	$K^{trans}(SSM)$	.97	.75	.90

**Figure 1**



## DCE-MRI Texture Analysis for Early Prediction of Breast Cancer Therapy Response

G Thibault, A Tudorica, A Afzal, S Chui, A Naik, M Troxell, K Kemmer, K Oh, N Roy, M Holtorf, W Huang, X Song