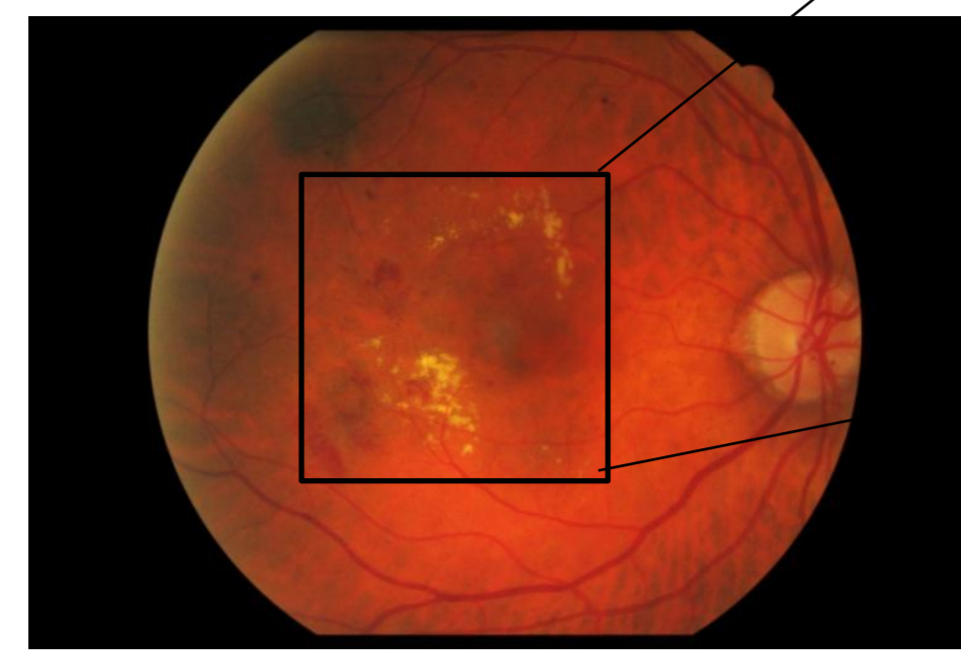
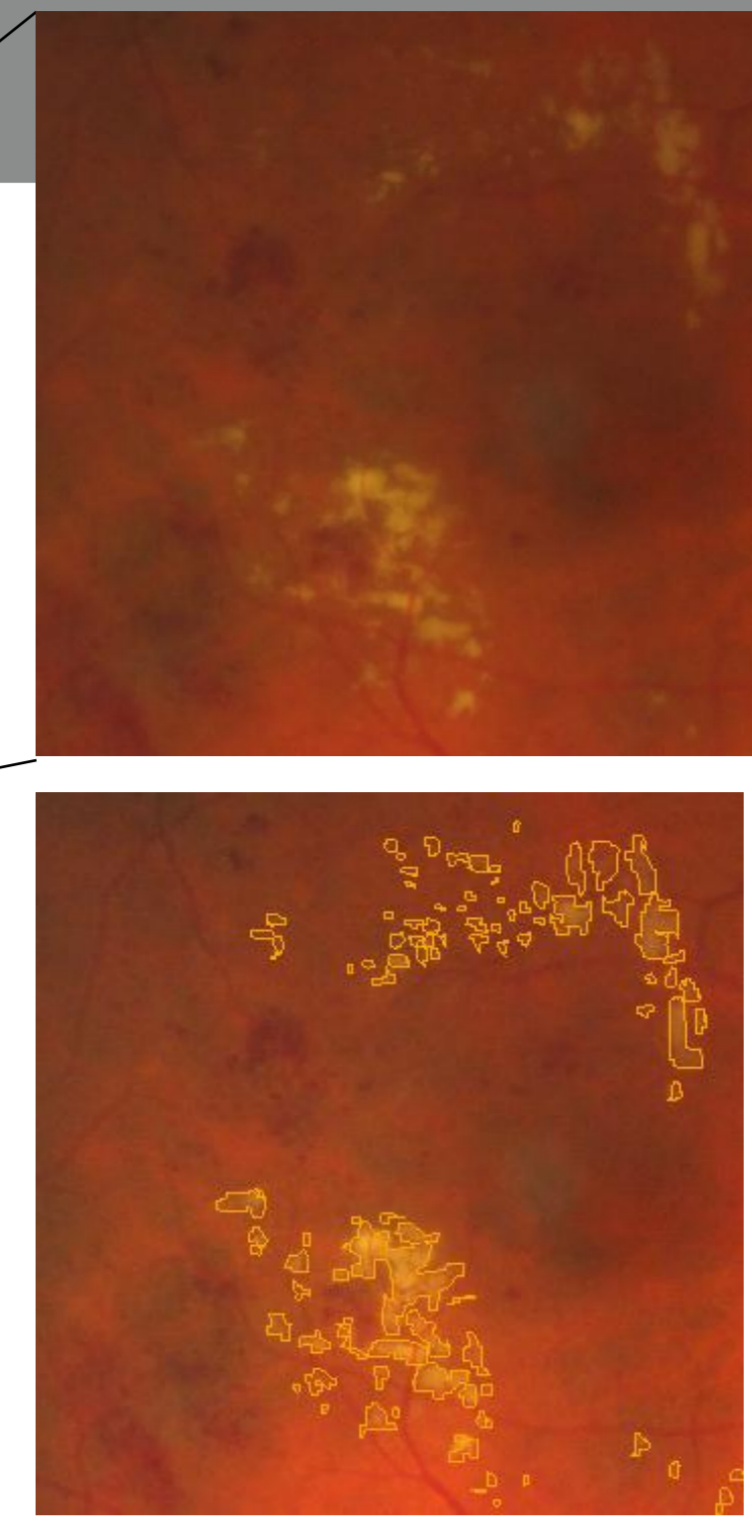


Introduction


- Exudates are early signs of Diabetic Retinopathy. In color retinal images, they appear as yellow-white structures of different sizes.
- A new method based on mathematical morphology and machine learning is proposed to detect exudates. It is validated on a clinical database **e-ophta**, extracted from the **OPHDIAT** telemedicine network, which consists of 82 images annotated by an ophthalmologist. The presented work has been performed within the scope of the **TELEOPHTA** project.



Exudates and annotations made by an ophthalmologist



Partners:



Authors:

X. Zhang, E. Decencière, G. Thibault, G. Cazuguel, G. Quéllec, R. Danno, B. LaÿA. Erginay, P. Massin, Z. Guvenli-Victor, A. Chabouis

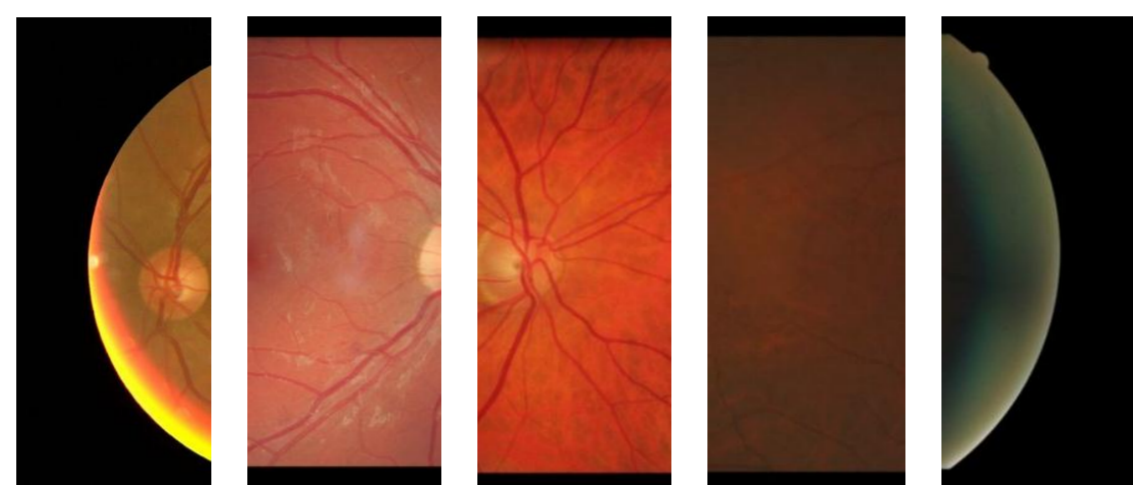
Financial support:



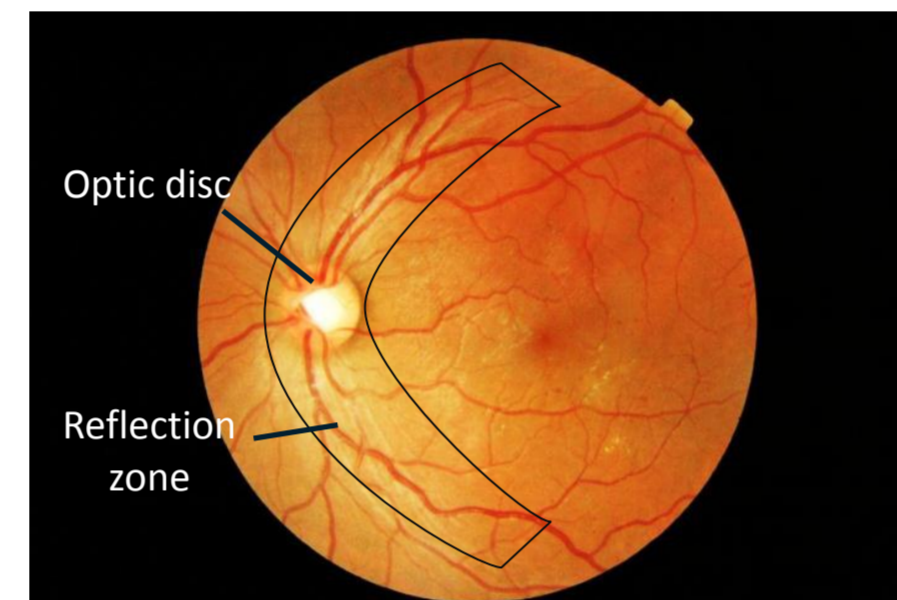
Disclosures: None

Main Limitations and Preprocessing

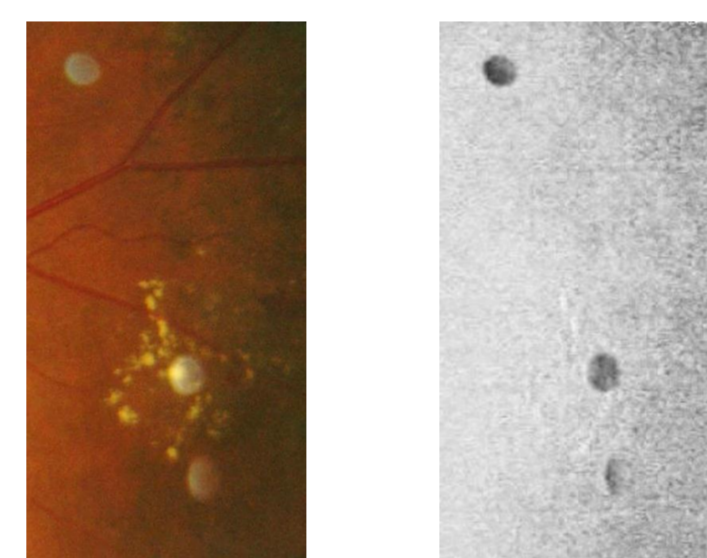
- Large variety of image quality in the clinical database, for example, size, color illumination, contrast etc.
- Exudates size, contrast and shape variability. A multi-scale approach is used to detect potential candidates.
- The optic disc could cause false detections. It is then detected and deleted beforehand.
- Reflections: zones along the main vessels and in the middle of the vessels. They are detected beforehand.
- Bright artifacts: detected on the saturation channel.
- Regions between two dark structures could cause false detections. A morphological inpainting is used to remove vessels and dark structures.



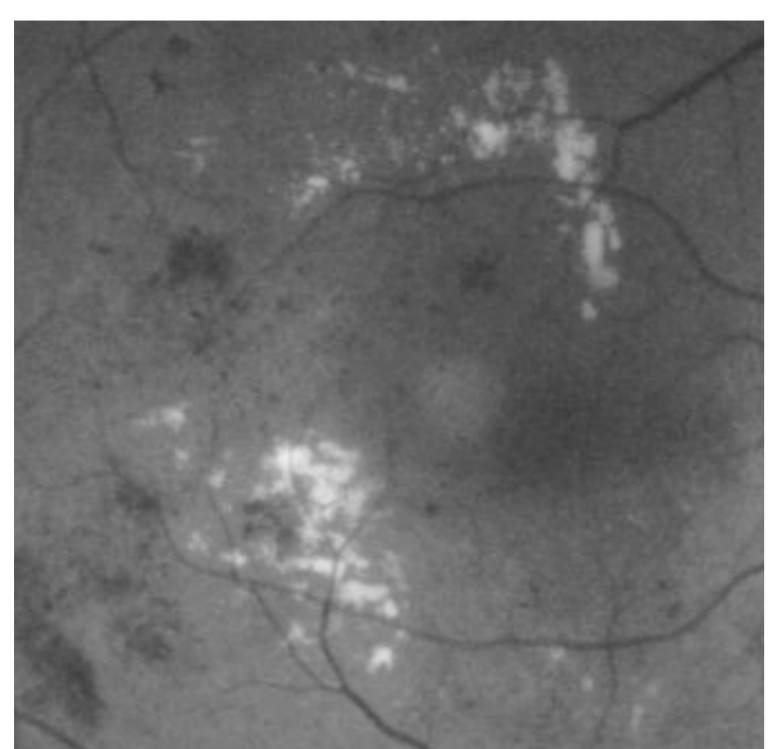
Different image types in the database




Optic disk and reflection zone



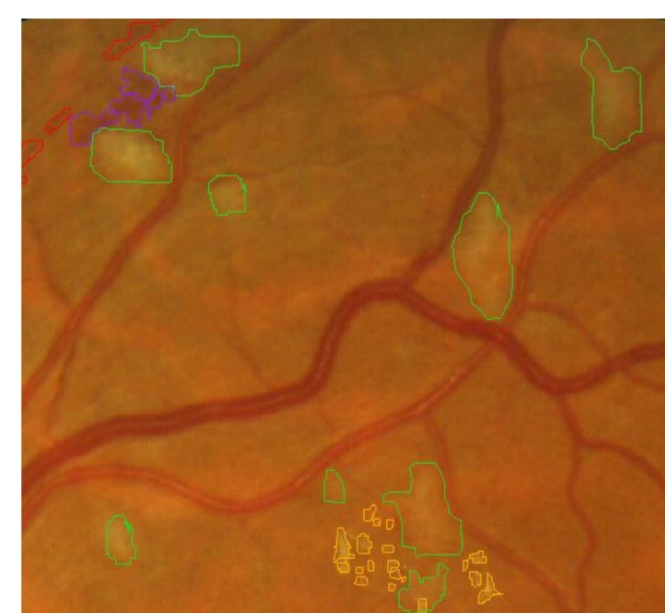
Bright artifacts and exudates in the color image and the saturation channel



Original image (green channel)



Inpainted image (dark elements removed)

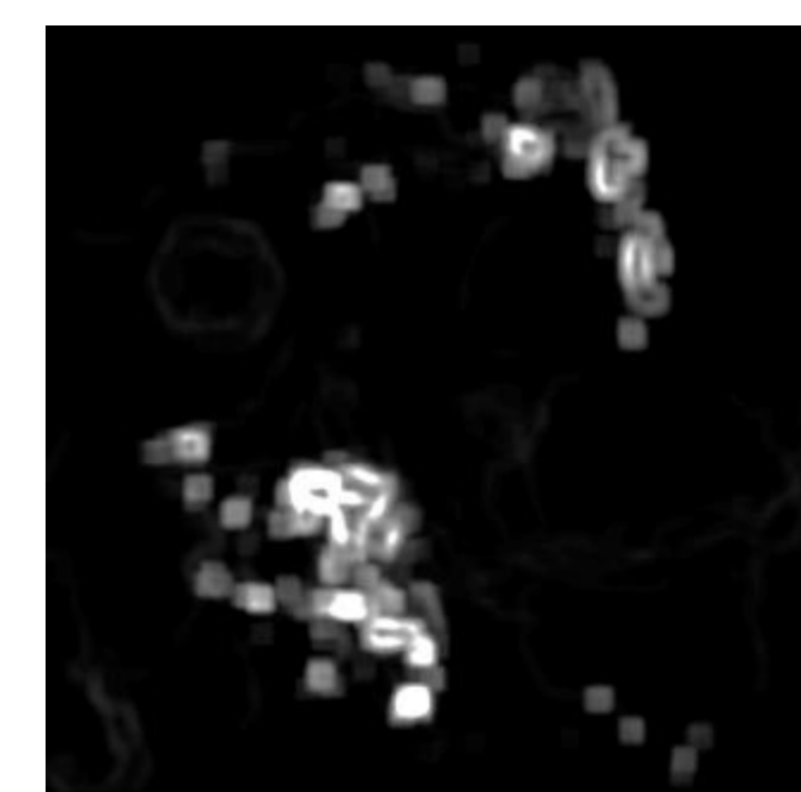


Cotton wool spots


Proposed Methods

Exudates candidates extraction


- Main candidates are detected using a local variance analysis and an ultimate opening.
- Small candidates are extracted by variance with a smaller window size and a top-hat operation.
- Local variance can give a good estimation of contrast change and provides possible regions where exudates are present. Since this transformation is size-dependent, a multi-scale approach is used.
- The morphological ultimate opening^[1] is a transformation which extracts the largest contrast for each pixel in a morphological scale space. It is less sensitive to the scale than local variance.



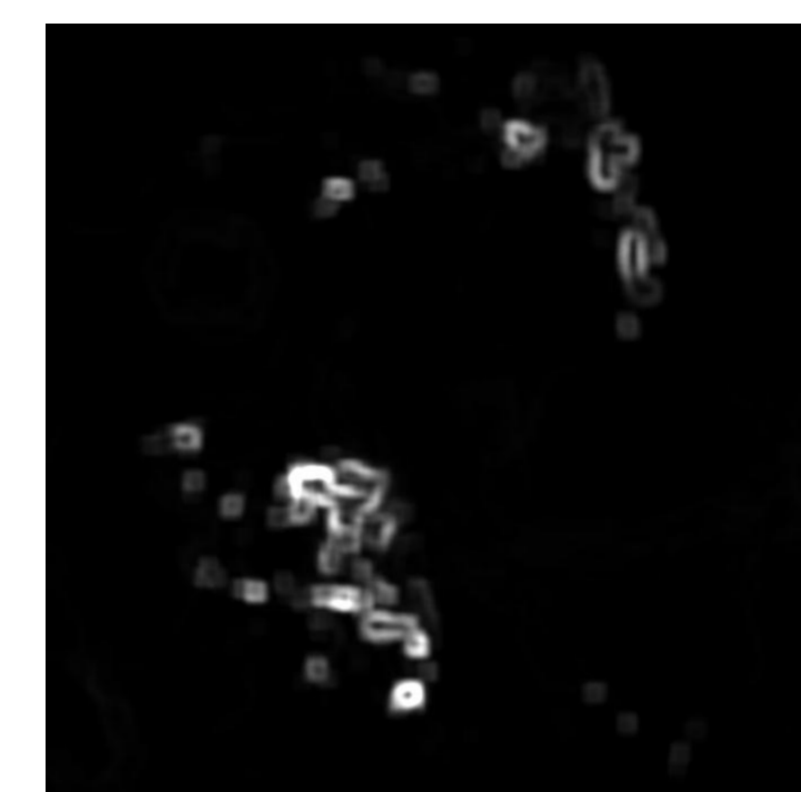
Local variance (large size)



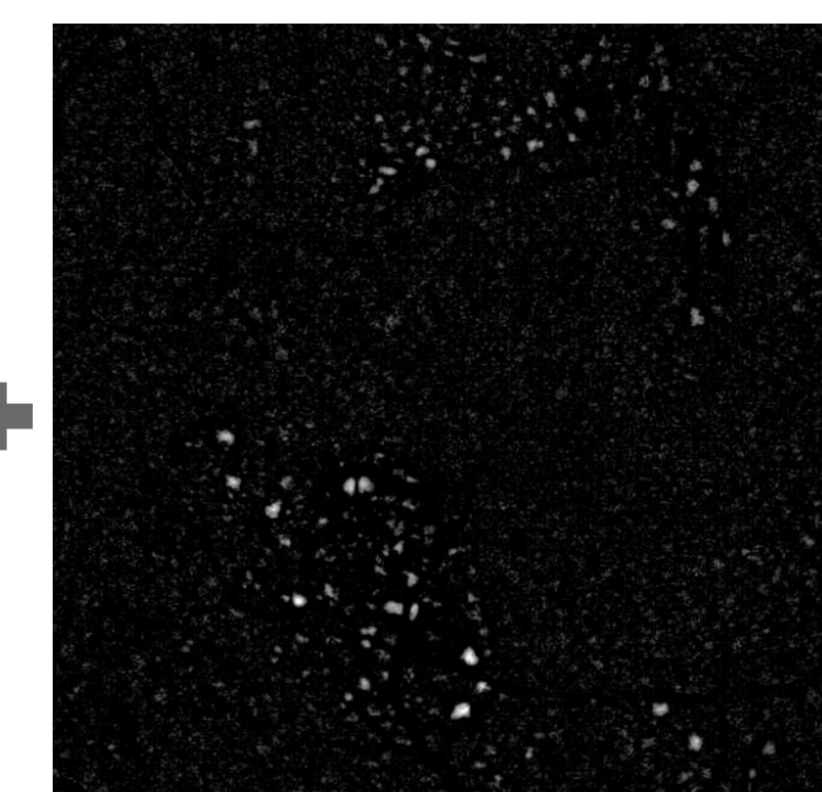
Ultimate opening



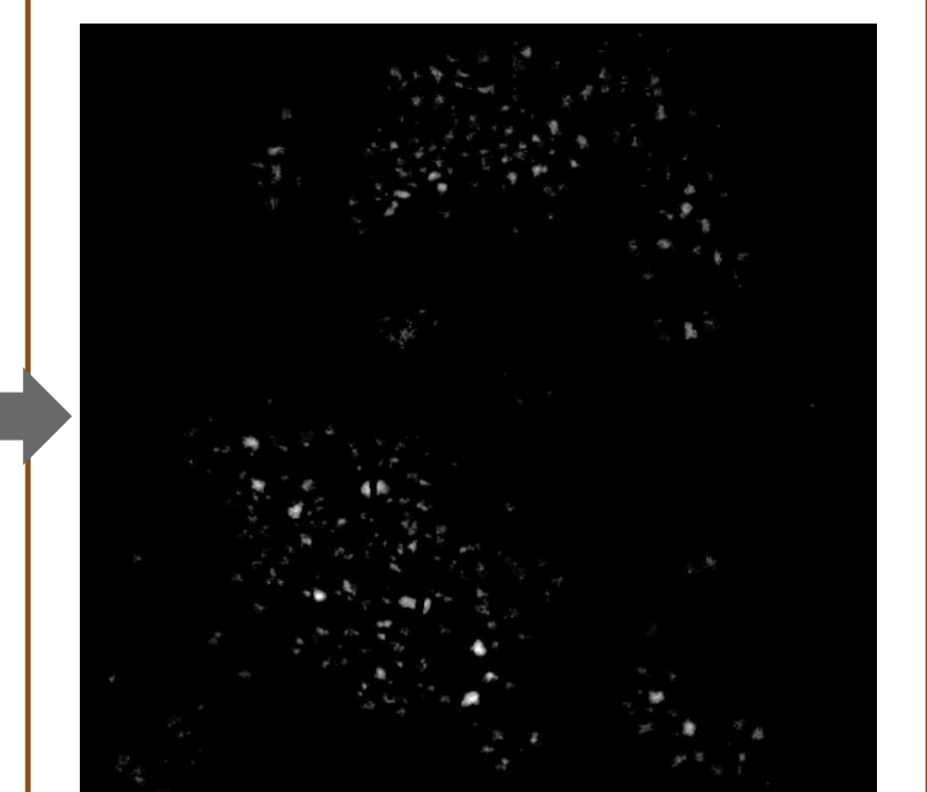Main candidates



Local variance (small size)



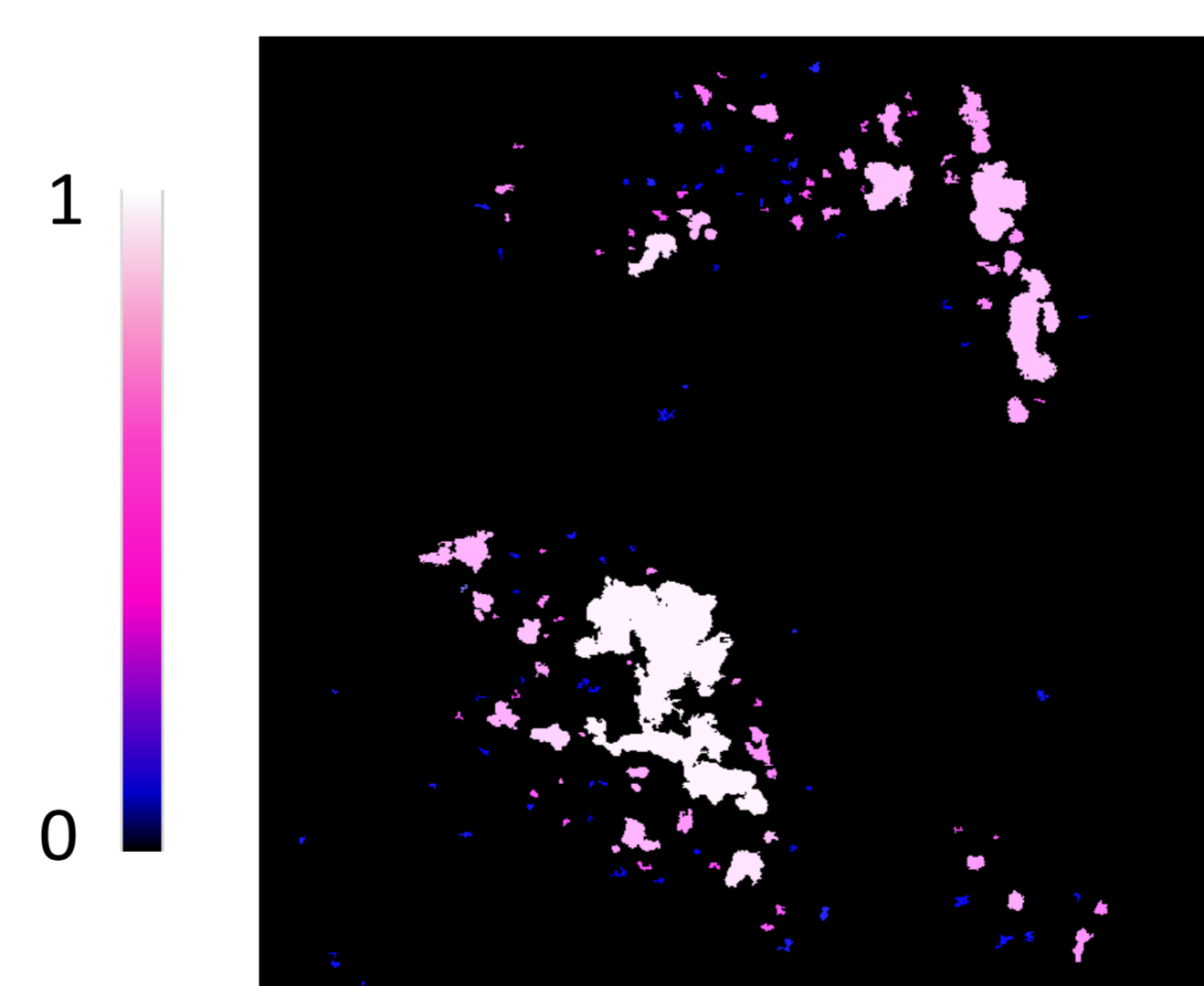
Top-Hat




Small candidates

Risk evaluation for each candidate:

- 23 characteristics are extracted (contrast, intensity, area, volume, perimeter, etc.).
- Classification by Random Forest^[2] provides a risk factor.



Final result (risk function)



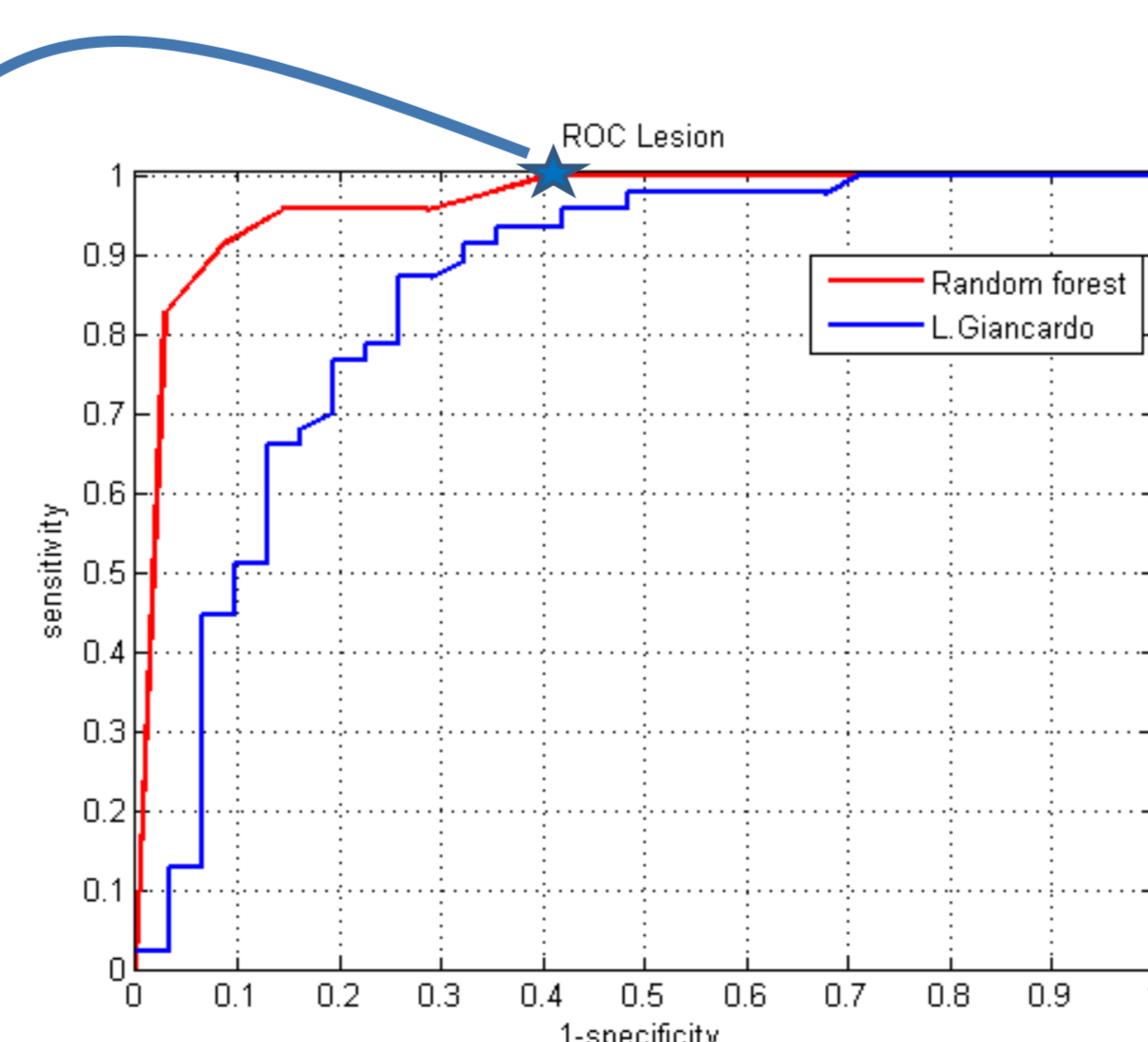
Manual expert annotation

Results and Perspectives

- Validation is done on 47 pathological images (all exudates have been meticulously annotated) and 35 healthy images. The performance of the method is evaluated by using the ROC curve computed according to the risk of presence of exudates in each image.
- The proposed method outperforms the algorithm by Giancardo et al.^[3] on the images of the considered database.
- The confusion matrix corresponds to the first point of the ROC curve without false negatives.

	Positive	Negative
True	47	21
False	14	0

Confusion matrix



- Future work: improvement of size, contrast and quality normalization in a heterogeneous database

[1] S. Beucher, "Numerical residues, Mathematical morphology: 40 years on", pp.23-32, 2005.

[2] L. Breiman, "Random forests", Machine Learning 45, 1, 5-32, 2001

[3] L. Giancardo, "Automatic retina exudates segmentation without a manually labeled training set", Biomedical Imaging, IEEE, pp.1396-1400, 2011.

